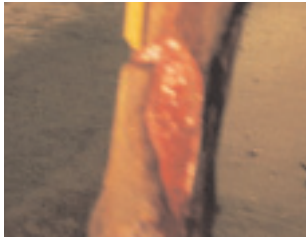

VET BIOSIST™

BEFORE AND AFTER TREATMENT

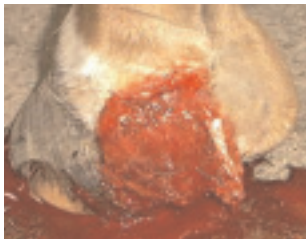


DERMAL

Left: Equine with below the knee injury.

Right: Four weeks post surgery.

Reference: Dr. Penny Dye, Dakota Hills Veterinary Clinic, Rapid City, South Dakota, USA.



DERMAL

Left: Nine year old male equine with an over-reach injury of the caudal aspect of the medial heel bulb.

Right: Thirty-one days after initial treatment.

Reference: Dr. Tony Page, Burnhouse Veterinary Center, UK.

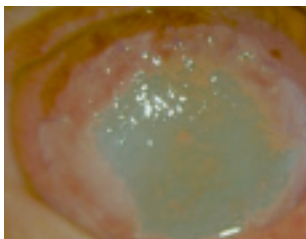


AVIAN

Left: Barn owl with full thickness skin necrosis.

Right: After surgery.

Reference: Stephen J. Divers BSc(Hons) BVetMed CBiol MIBiol DZooMED (Reptilian) MRCVS Diploma in Zoological Medicine, Ithica, New York, USA.

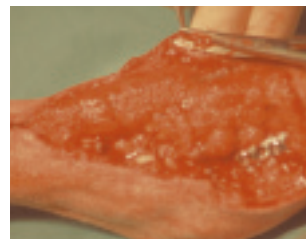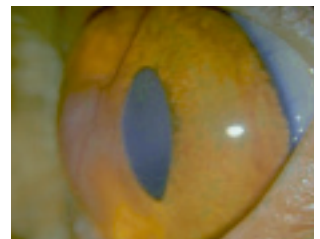


OCULAR

Left: Three year old Persian cat presenting with deep stroma ulcer.

Right: Three months after surgery.

Reference: Dr. Monika Hund, Germany.

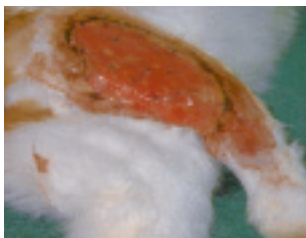
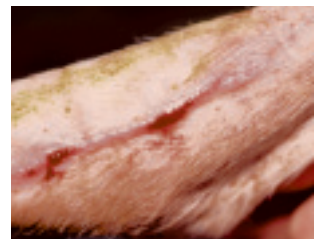
DERMAL

Left: Ten month old crossbreed American Sheepdog with a degloving injury.

Right: Thirty-two days after surgery.

Reference: Drs. Michel Baron and Isabelle Valin, Clinique vétérinaire chirurgical, Maisons Alfort, France.



DERMAL

Left: Ten month old cat with excised abscess.

Right: Three months after surgery.

Reference: Janine Badylak, USA.

